Edition

1

DR. ASHISH BABHULKAR

D.Orth.,DNB.Orth,FRCS(Tr.&Orth.), MCh.(Orth.)(Liverpool,UK)

Pune Shoulder Rehabilitation Programme-PSRP

6th Sep 2007

CONSULTANT SHOULDER & JOINT REPLACEMENT SURGEON

DEENANATH MANGESHKAR HOSPITAL, PUNE

SANCHETI INSTITUTE FOR ORTHOPAEDICS & REHABILITATION, PUNE

Dr. Ashish Babhulkar

3, Anant, Income Tax Lane
Off Karve Road
Pune 411004
Phone 2545 0404 • Mob +91 98222 18550
Email docshoulder@gmail.com • Web www.jointandbones.com

Table of Contents

Chapter

1

Introduction

Basics about the shoulder joint – Definition, anatomy, biomechanics, clinical nomenclature & exploding common myths.

The shoulder joint is often loosely talked about as the gleno-humeral joint. In reality the two are quite different. The shoulder joint encompasses the gleno-humeral joint along with scapulothoracic, acromio-clavicular & sterno-clavicular joint, all in toto. If any of these four joints are affected the shoulder function will be severely compromised. The net result of each is the same – pain & stiffness. The treatment – as a therapist or a surgeon – has to be directed at the joint that is at fault. Present day therapy is often directed at the gleno-humeral joint irrespective of the site of pathology. By the time the patient presents with a shoulder problem they have developed compensatory mechanisms to overcome there primary weakness or dysfunction. For example the patient may start with an infraspinatus tendinoses and gradually develop scapular dyskinesia as a compensatory measure. With progressive overhead impingement the supraspinatus will weaken worsening the impingement and leading to shoulder stiffness. Hence it is important to find the root cause and on correction of the primary weakness will help overcome the secondary decompensation problems.

Scapular Principle – Ben Kibler's contribution

The relationship of the scapula to the Shoulder joint is like that of the foundation to a building. However strong the shoulder muscles, they are of little use without a sound scapular anchor. Kibler introduced this concept and revolutionised shoulder rehabilitation. Normal scapular function would envisage two aspects

1) Scapular muscle strength, including that of rhomboids, serratus anterior and to some extent levator and lower trapezius.
2) Apart from strength, the scapulo-humeral rhythm has to be normal. A dyskinetic scapula will alter the length tension relationships of the scapulo thoracic muscles and lead to fatigue. Dyskinesia itself encourages impingement and supraspinatus tendinoses.

Without either of these two parameters it is difficult to anticipate normal shoulder function.

Scapular Dyskinesia

Abnormal scapulo thoracic rhythm is termed scapular dyskinesia. This is a non specific response to Gleno-humeral pain / injury / pathology - Ben Kibler

Definition of normal Scapulo thoracic rhythm

Simply said the rhythm is normal if it is smooth, equal and symmetrical on both sides when compared on active elevation and abduction. It is a motor pattern learnt through practice and repetition.

This is normal tracking of scapula which ensures smooth movement of the greater tuberosity under the acromion without pain or impingement. Normally this is said to occur in a 2:1 ratio though the ratio is not proportionate from start to end.

Golf Ball concept

The shoulder joint is a ball and socket joint like the hip joint. The difference lies in the fact that it is far more mobile. This mobility is obviously at the cost of stability vis-à-vis the hip joint. The glenoid articulating with the head of humerus is

similar to the golf ball on a tee, with minimal coverage. The onus of stability lies on multifactorial parameters such as concavity compression, vacuum effect, strong rotator cuff, intact labrum and dynamic factors such as balance between internal and external rotators and proprioception.

The concept of Impingement

One must be aware that for complete pain free abduction to occur, the greater tuberosity has to clear the acromion. To ensure this arc, the person has to have a normal anatomy, good cuff strength, normal scapulo-humeral rhythm and achieve reflex external rotation as the arm exceeds 90 degrees abduction. Conversely, any shoulder problem – a minor one like joint laxity, supraspinatus tendinoses or a major one like bankart tear, rotator cuff tear or winging of scapula will lead to impingement. Therefore every shoulder problem will manifest as impingement as a presenting feature.

Frozen Shoulder / Adhesive Capsulitis

Most if not all shoulder conditions get labeled as “Frozen Shoulder”. Not always is this true. In reality frozen shoulder is a rather rare condition. By definition “frozen shoulder” means global restriction of external rotation and abduction after having ruled out all causal conditions such as, labral pathology, rotator cuff tear and Acromio-clavicular joint arthritis. This is perhaps more accurately described as Adhesive capsulitis. Terms such as periarthritis have an unscientific undertone. As you are now aware, any chronic shoulder problem will present as a stiff joint. In any chronic shoulder problem, as any lay person would suggest, the joint is “frozen” but the true cause of such an event must be evaluated by history, clinical evaluation and USG or MRI tests for the shoulder. Very often a preexisting lesion will be diagnosed and until we address this specifically the shoulder joint will not yield to the rehabilitation programme. Frozen shoulder as a term would suggest a rather old terminology may not reflect the rapid advances achieved by modern shoulder science.

Shoulder conditions temporal profile

Most shoulder conditions are quite sharply demarcated by age. So the younger patients generally have instability which may be a labral tear or capsular laxity with multi directional instability. Also in the younger age groups trauma is a common aetiology before symptoms begin. The middle ages present with impingement either primary or secondary. The elderly will suffer commonly from rotator cuff tendinoses or tear and related problems. The very old patients over 60 years of age can have a preponderance of arthritis – gleno humeral or AC joint. Although there is a grey zone between these age groups the outliers are small in number and principally the clinician can use the age of the patient to guide him to the diagnosis.

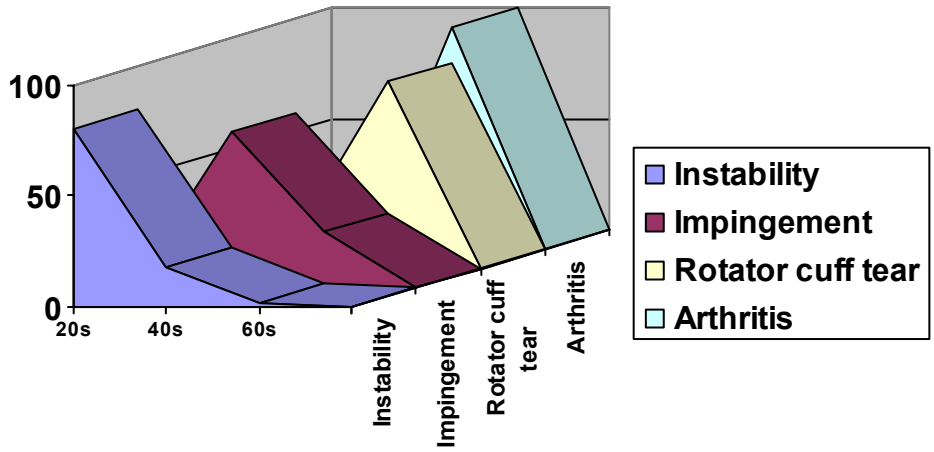

Chapter

2

Pune Shoulder Rehab Programme

Principles of shoulder rehabilitation – do's & don'ts

The entire success of shoulder rehabilitation relies on normal scapular function & cuff strength. On the scapular side the emphases is essentially on Rhomboids, Serratus Anterior along with levator scapulae & lower Trapezius. The strengthening programme is reasonably straight forward. Patients with poor posture, kyphosis and elderly patients are difficult to train and emphasis should be placed on correct techniques which can be assisted by the therapist. Restoration of normal scapulo-humeral rhythm is more difficult and requires experience and practice. Most patients with chronic shoulder problems lose their sense of proprioception. Their perception of correct scapular tracking is absent. To restore normality one has to rely on sheer exhaustive repeatability and help the patient develop their proprioception sense by comprehension of what is right & what is wrong.

Phasic programme

The **Pune Shoulder Rehabilitation programme (PSRP)** has been designed to ensure complete patient compliance and at the same time providing optimal rehabilitation in the minimum time interval. The programme for Primary impingement, rotator cuff tears and arthritis is designed as a bi-phasic programme. The first phase is totally supervised for about two weeks followed by a home programme for about four weeks. Patients are expected to get 50% better by the end of phase I. This is

measured as a VAS score before and after, passive ROM assessment, UCLA score and patients themselves are asked to plot their improvement in three groups – pain, movement and strength.

Phase I

Phase I essentially comprises of scapular strengthening programme along with capsular stretching exercises if the shoulder is stiff. Patients who have pain and disability without shoulder stiffness can be offered scapular setting exercises in lieu of the capsular stretching exercises. Poor posture, pectoralis minor contractions and Kyphosis of thoracic spine also have to be corrected. This is a crucial time for the therapist to gain confidence of the patient. From the patients perspective this can be a painful experience, especially so on the first few days, due to the dramatic increase in stresses on the shoulder joint. During the capsular stretches, all patients tend to be apprehensive and resist the stretches going into spasm. It is important for the therapist to continuously distract the patient with plenty of shop talk and at the same time concentrate on gentle stretches. Each patient has his/ her own individual parameters of tolerance. Each therapist has to in turn exceed these restraints, by marginal fractions each day. The capsular stretches must be done in the sub pain threshold and it is always the experienced therapist who gets the best out of patients.

Therapists who are new to this programme must at all times perform the stretches with the patient in supine position as the firm bed helps stabilise the scapula. If scapular muscles remain weak & unstable, then stretching in sitting position can encourage impingement, leading to pain and further non-compliance from the patient.

We have always noticed that the pain starts improving sometimes on the very second day of rehabilitation if the scapula setting is successful and the cuff muscles start to recruit. By the fourth day most patients have had a noticeable pain relief. Lack of response to pain would suggest that both the rehab has been incorrect and scapula is not stabilised along with cuff continuing to be poorly recruited. On the other hand patients with a structural deficit – such as a cuff tear or a labral tear can have a poor response to the PSRP.

Anterior Capsular stretches – self stretches

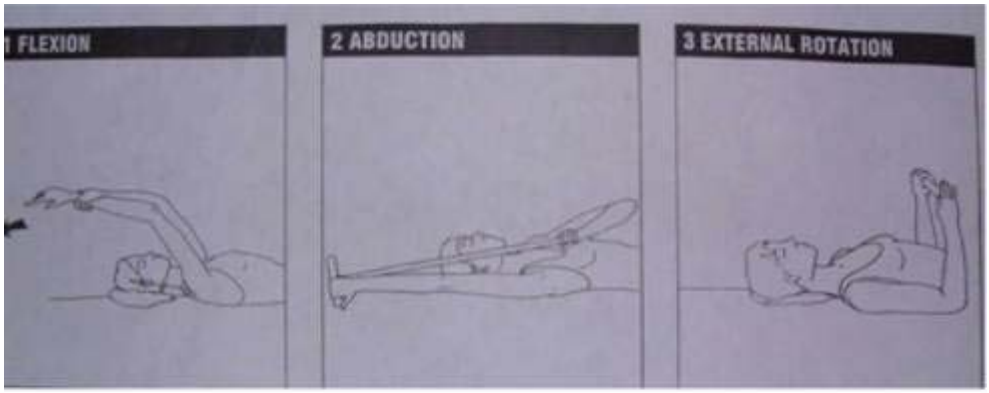

1. Self stretching of inferior capsule in forward flexion. 2. Self stretching of inferior capsule in abduction. 3. Self stretching of anterior capsule in external rotation with the shoulder in neutral.

Stretching of the anterior capsule achieves improvement of external rotation. The anterior capsule tends to be a thick obstinate structure which yields only with time particularly in Diabetic patients and longstanding contractures. The anterior capsule should be stretched to its tolerance limit and held in the terminal position to a count of 10. This should be done as 10 repetitions of each stretch. The initial stretch may be done with the shoulder in neutral followed by shoulder in 90 degrees of abduction (if possible) for similar repetitions of ten each. This helps stretch different segments of the anterior capsule.

Inferior capsule stretches

These involve guiding the shoulder, without scapular elevation to occur, in forward flexion and

abduction. Similarly the therapist must reach to the sub maximal point of patient tolerance and hold for 10 seconds with ten repetitions each. One must be careful to avoid impingement, especially in abduction, for fear of provoking pain. Experienced therapist will realise that forward flexion yields much earlier than abduction. This is because abduction improvement follows improvement of external rotation. In fact it is our experience that the progress of external rotation and abduction is interlinked.

Posterior capsular stretches

Occasionally the posterior capsule can behave like a tenacious unrelenting structure and restoration of internal rotation can thus be delayed. This is a very functional movement that a patient requires to reach his/her mouth and back and scratch the back or tie their bra strap. Stretches should be given in forward flexion adduction across the body and adduction internal rotation manoeuvre behind the back. Patients can be taught self stretches with a towel to lift the affected hand behind their back.

Posterior capsular stretch 2

CAVEATS
➢ Watch for pain
➢ Avoid scapular elevation
➢ Every week 10 degree +
➢ IFT/USG for pain relief

90-90 internal rotation stretch

By far the most effective stretches are the sleeper stretches with the shoulder in 90/90 abduction at the shoulder and elbow. Both internal and external rotation stretches can be effectively given yielding early results.

Scapular strengthening

The emphasis is again on the Rhomboids, Serratus anterior, and Levator scapulae along with the lower Trapezius. All strengthening exercises are done with progressive resistance with therabands and against gravity. The therapist must understand the correct technique for each muscle and confirm whether the required muscle is recruited during the particular exercise. So often wasting or pain inhibition will allow a neighbouring muscle to be contracted as a compensator – this is a common problem for failure of the programme. Each muscle shoulder contracted for about 10 seconds followed by ten repetitions. With each passing day the repetitions and the old time can be progressively increased. The therapist must confirm with palpation that only the desired muscle is contracting without participation of the compensating muscles.

Therabands

Therabands are useful to follow a closed chain exercise programme against resistance. Closed chain principle is all the more important in the shoulder joint which tends to be unstable. The knee joint can tolerate open chain exercises in most conditions although it is again preferable to do closed chain rehab. For the shoulder joint which is

inherently unstable and prone to impingement the entire PSRP is based on the closed chain principle. Rehabilitating the shoulder in the open chain fashion introduces shear between glenoid & humeral head worsening the instability. Therabands are colour coded bands ranging for yellow to red, followed by green, blue and black in increasing range of resistance. PSRP does not advice starting Therabands training on day one. Principally one must wait for some semblance of scapular control and increased tone of the scapular muscles. Hence depending on patients' physical fitness and response to Phase I, Therabands are started only after scapular stabilisation is achieved. This could be by day one or day four. Bracing the shoulders (often referred to as Ground Zero) helps overcome the pectoralis minor contracture and braces the scapula away from the greater tuberosity. Also while strengthening supraspinatus the maximum elevation allowed is 60 degrees in a plane parallel to the scapula otherwise this can provoke impingement, leading to pain and non-compliance. Smooth gentle movements without any jerks are advised. Maintaining a hold of ten seconds followed by ten repetitions is standard practice. These can progressively be increased daily. It is the therapist's duty to supervise correct technique of Therabands exercise as patients are seen to frequently do these wrongly. Eccentric strengthening is also emphasized during rehabilitation i.e. controlling return movement during exercises with elastic bands.

Scapular Stabilising Programme

(Scapular proprioception restoration / Scapular setting)

There are three main components of the Scapular Stabilising Programme.

i) Setting in Neutral
ii) Assisted Setting with Passive control
iii) Dynamic Control / Dissociation.

It is essential that muscle imbalance problems are addressed to facilitate optimal scapula stability and scapulo/gleno-humeral alignment to minimize the risk of impingement and/or instability.

Setting in Neutral

The scapular muscle strengthening programme addresses the scapular stabilisation in neutral. The focus is on strengthening essentially Rhomboids and the serratus anterior. However, along with these exercises, the levator scapulae with the lower trapezius are also exercised. The prone rhomboid strengthening is done in 3 steps. Step I is in prone & replicates the standing bracing exercises by rolling the shoulder blades (Scapulae) towards each other. Frequently patients mistake this for levator strengthening and end up shrugging their shoulders. Once shrugged it is difficult for the shoulders to brace themselves. Therapists need to practice this exercise a few times themselves to achieve the correct movement pattern. The correct exercise

involves rhomboid contraction for upto ten seconds followed by ten such repetitions to start with.

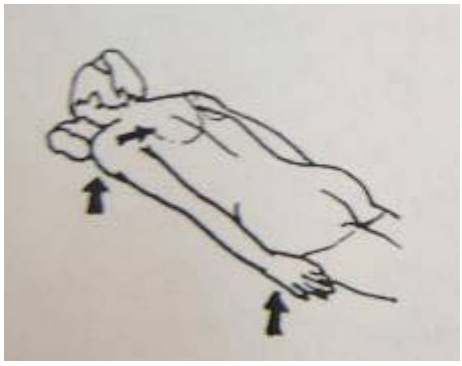

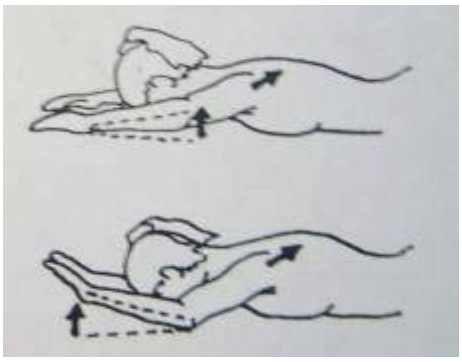

Step 1 Step 2 and Step 3

Step 2 & 3 involve recruiting different segments of the rhomboids and can be quite difficult to do for elderly, obese and patients with stiff shoulders. Hence we advocate step 2 & 3 only for the young instability patients as it is preferable to do few exercises but with the correct technique. Step 2 is a variation of the same theme where the patient lies prone and braces the scapula and then with flexed elbows maintains the palms in contact with the bed and lifts the flexed elbows upwards. The patient does not bear any weight through the palms but only lightly keeps them on the floor or bed. Step 3 is a further variation where instead of the palms the patient makes contact with the flexed elbow and lifts the palms up in the air. Similarly the patient does not bear weight through the flexed Elbows. Each of step 2 & 3 exercise is done for ten seconds hold followed by ten repetitions.

*** Patients should progress from Step 1 to 3 only after achieving proficiency at each stage.**

Scapular muscles can also be more effectively strengthened with therabands.

Assisted Setting with Passive control

With the therapist facing the patients scapula the patients affected arm is taken through the full arc of forward flexion passively. One hand of the therapist is supporting the inferior angle of the scapula and the other outer hand is supporting the hand to control the downward movement of the arm. The arm has to be brought down very slowly as the patient is required to develop cognition of the scapular position and also regenerate proprioception sense of the scapulo-humeral rhythm. The restoration of proprioception pathways is a time consuming therapy. Repetitive simulation of the correct movement pattern will help the patient take cognition of the correct rhythm. The scapular stabilisation program is recommended for three weeks during which patients are encouraged to understand correct scapular positioning and start to grasp control of their scapular positioning. Some intelligent patients, especially with a medical background, will achieve this within two weeks whereas chronic patients with muscle imbalance do take more time.

Dynamic Control / Dissociation

After achieving the goals of the previous two sets the patient is usually ready to go on the home exercise programme. Apart from the other standard rehab programme the younger instability patients are encouraged to develop dynamic control of their scapular rhythm &

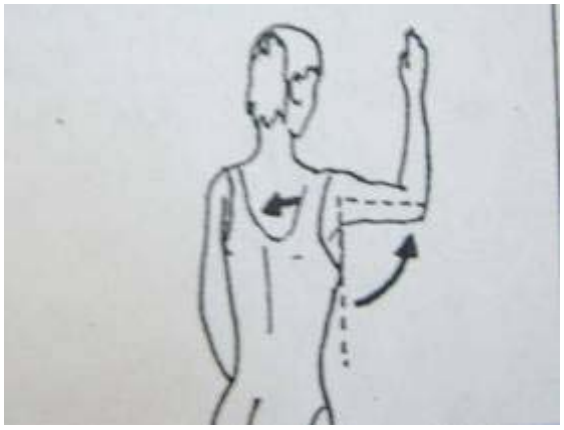

movement. By now patients have developed an awareness of their scapular position and at home are advised slow forward flexion (upto 90 degrees) and abduction (upto 60degrees) exercises. During this 90/60 degree range of flexion/abduction patients should ideally achieve movement independent of scapular movement. Patients are warned about the fact that if they lose control over the scapular movement they will have to restart supervised proprioceptive exercises all over again. It is our experience that most patients develop their independent scapula control over three weeks and only patients with severe
Scapular instability have had to extend their program for a total of six weeks.

Presetting the scapula & pattern correction

Primary recruitment of the cuff muscles a fraction of a second before the movement starts is important to firmly anchor the head of the Humerus centrally into the glenoid providing a sound fulcrum. Merely strengthening the rotator cuff is of little use if the scapula is not preset into its anatomical location and concurrent contraction of the cuff muscles. For example external rotation may encourage anterior translation thereby inhibiting the subscapularis muscle and upsetting the balance of the shoulder joint. It is also common to see patients with weak external rotators with associated scapular dyskinesia and often tennis elbow. Without scapular setting strengthening the infraspinatus may not be possible. Recognizing the pattern abnormalities is an important step in treating MDI (multi directional instability patients). Often even in the conventional unidirectional instability patients compensatory patterns do occur and must be corrected during their supervised rehab. From the Bailey group from England, it is well understood that a weak cuff is

almost always associated with scapular dyskinesia and abnormal recruitment of pectoralis major and latissimus dorsi. A static testing of the rotator cuff, especially in the young patient can be erroneous and may not be relied upon.

Deltoid Strengthening exercises

Deltoid responds quickly to resisted exercises. However in the absence of rotator cuff function, the deltoid contraction will result in proximal migration of the humerus (Refer to Chapter 1 – Introduction). Basically the cuff contraction helps bind the head of the humerus to the glenoid resulting in effective abduction by deltoid without causing impingement. Hence, in patients with a rotator cuff tear or dysfunction, or post operative rotator cuff repair patients deltoid strengthening should not be taken up. The therapist should be awake to this problem and hence his/her clinical assessment is very important.

Dynamic Functional PSRP


Rotational stabilisation with Elbow wrap technique

Since January 2007 PSRP has been improvised to include more dynamic exercises which may replicate functional activities. In the older version of PSRP individual muscles were strengthened optimally. However in itself this is not enough. It was realized that there is an inherent balance between agonists and antagonist muscles. Nowhere is this more important than achieving balance between Subscapularis and Infraspinatus. Similar co-contractions are activated during most overhead function. It was realized that abduction is not merely a result of deltoid and supraspinatus but a gamut of other muscles contracting proportionally. It is vital to ensure that the co activators are stimulated reflexly and adequately. Here I am obliged to Phil Page from Theraband academy for his contribution

to the functional programme that was added to the existing PSRP. The functional programme involved two basic exercises – the rotational stabilization was performed with a special elbow wrap (refer figure) of a two meter therabands and the elbow was maintained in 90 degrees flexion at all times. To start it was kept in 90 degrees forward flexion and smoothly taken to the 90 degree abducted position and held for 10 seconds. Such repetitions were performed ten times. The 90-90 strengthening exercise was performed with the arm in 90 degree abduction and also elbow in 90 degree flexion. The hand with the stretched therabands was then moved into internal rotation and external rotation simultaneously maintaining the arm in 90 degree abduction at the shoulder.

It is important to understand that these dynamic functional exercises should be done only at the tail end of phase I. In the absence of good rotator cuff strength and stiff shoulder these would be either impossible to do or may incite pain. I believe that the reflex co activation and proprioception control are restored much better and quicker with these dynamic functional exercises.


90 90 strengthening for Infraspinatus & Subscapularis co activation

Core rehabilitation

Core stability has become a whole science in itself in the last decade as all manner of sports professionals have realised how critical it is for the inner core of the body, namely those joints closer to the spine, to be supported by the postural muscles designed to do so. For the shoulder, the critical areas are the lumbar and cervical spine, and the scapulo thoracic joint. If these areas are not stable, then significant extra loading and strain will be passed on to the shoulder joint. Core rehabilitation has been the foundation of success in treating athletes and back ache patients. A patient with core instability has the same chances of suffering from back ache as shoulder dysfunction. Since the whole body is a closed kinetic chain, weakness of the link elsewhere can have significant impact on the other joints. We have applied the same principles of sports rehabilitation to our day to day patient with success. As in a tennis player lower limb control and stability have a direct

influence on shoulder joint. Similarly a housewife with a weak core and poor calf muscles will decompensate at her shoulder joint due to her continuous overhead work in the kitchen. They are taught to perform a single heel raise for a count of ten followed by a gentle release of the heel.

The stability of the lumbar spine is achieved by the combined effects of transversus abdominis and multifidus acting on the thoracolumbar fascia. Keep in mind that this is

easier for some than others, depending on how your body has been trained – for instance, ballet dancers will find the stable position of the neck comes naturally, whereas wrestlers may struggle to maintain their core. Activating the muscles is the first stage of the learning process. Hence it is complimentary for all patients recruited into phase I to be taught a basic core rehab programme. This is

taught to them once and since it is fairly simple they are asked to continue the core exercises at home in a progressive manner. It is our experience that the transversus is invariably either poorly recruited or is recruited rather late. The major emphasis in core rehab remains transversus recruitment. Patients are taught the ab crunches with their hands on their abdomen to give them a bio feedback and also to ensure that the abdomen in not pushed out due to compensation by the rectus muscle. The patient is asked to tuck their tummy in and hold their breath. To explain it easily to the patient, they are asked to focus on their umbilicus and attempt to draw it into their abdomen towards the back. In addition they can be asked to close their anal sphincter and contract their perineal muscles as if they are holding back the urine in their bladder. These various maneuvers help patients recruit their transversus. In addition to transversus, eccentric calf contraction by performing a hold on the single heel raise and counting till 10 followed by a slow release is also taught to the patient. Improvement in weak core and calf muscles helps restore stability and facilitates the rotator cuff and its normal firing patterns.

Chapter

3

Modalities – Steroids / IFT / SWD

Intra-articular Steroid injections

Therapeutic/ Diagnostic/Assistive

Intra-articular steroid injections have been used for every shoulder pain for may years, and that to quite effectively. Steroids are effective anti-inflammatory agents and if targeted at the organ of interest – such as intra-articular they act more specifically. It is a myth that locally given steroids do not influence the blood sugar levels. In fact very often in bilateral inflammatory pathology steroid injection in one joint will help reduce the inflammation of the opposite joint. Blood sugar levels also can rise dramatically. Steroids should not be used liberally. Only in the presence of inflammation are steroids effective. Chronically painful and stiff shoulders do not respond to injections. In the presence of rotator cuff tears, injecting steroids into the shoulder joint will eliminate any remaining healing potential at the tear site. The steroids do not cure the shoulder problem unless it is primary

impingement. The injection does have a diagnostic role as only genuine shoulder impingement patients will respond positively. Patients that do not respond must be worked up for cervical spine disorders, thoracic outlet syndrome and polyarthropathy. Steroids have a dramatic effect on the acute calcific tendonitis of the shoulder. At the same time a chronic calcific deposit within the supraspinatus in the absence of inflammation will elicit no relief after an intra-articular injection.

CAVEATS
➢ Acute calcific tendonitis
➢ Avoid adding lignocaine
➢ Only if PSRP failed
➢ AVOID in cuff tears
➢ Strict asepsis

Chapter

4

Surgical Protocols

Patients of SLAP tear, Bankart repair and multidirectional instability require additional inputs in the form of scapular setting exercises & restoration of scapulo-humeral rhythm. Some of these young patients are keen to pursue an overhead sports hobby, in which case they need to attend the third phase, six months after surgery or normalisation before they enter their desired sports programme.

Principles of protected phase & rehab phase

The foundation of post surgical rehab is almost similar to the conservative therapy. The main differences are with reference to individual conditions and repaired structures. All tendons, cartilages and labrum repairs take about six weeks to heal. The first six weeks are thus the protective phase where mobilization is permitted but within limits. A progressive mobilization programme for Bankart repair and cuff repair will help regain cuff strength & shoulder function quickly. There is some evidence to suggest that early mobilization is more likely to restore normal function and reduce the incidence of post op pain relief. Most surgical procedures on the shoulder are arthroscopic. Surgeons prefer suture anchors to repair the damaged tissue. These

are made of titanium and poly and have a very good pull out strength (from 50 Newton to 470 Newton). The goals in modern surgery are to encourage mobilization without compromising on the repaired tissue integrity. Hence progressive mobilization should be carried out from the 3rd or 4th post-operative day once the operative pain is not a hindrance. The therapist must be careful not to provoke pain as this could bring about reflex spasm of the antagonistic muscle jeopardizing the repaired tissue. There are prescribed goals to be achieved at each stage after surgery although some patients are psychomotor artistes and achieve their goals quicker whereas others are maladroit and achieve their goals very late with a lot of effort. It is this skill that a therapist needs to develop, to identify the character of the patient and push him/her towards a redefined goal. It is unrealistic for all patients to reach their destination at the same time with the same ease. The therapists' responsibility is far greater with the post-operative patient as a surgical repair is at risk, patients tend to be more apprehensive after surgery and the patient has also spent a lot of money and time towards surgery.

In general shoulder movement upto 90 degree of forward flexion and 60 degrees of abduction is safe and does not put significant pressure on the commonly repaired tissue. Exceptions may be severely osteoporotic fractures of the proximal humerus and some difficult shoulder joint replacements. So unless a surgeon has explicitly written to avoid mobilization the above safe range may be freely started.

Scapular exercises must be started at the earliest along with posture correction. In the initial week only bracing and levator scapulae exercises are tolerated by the patient and I advice them to do these for 10 minutes every hour. By the third or fourth post-op week the increased ROM permits rhomboids and serratus strengthening. In the later days patients can freely perform all the scapular exercises including the prone scapular sets in neutral (refer page 9). Along with the Scapulars, ROM assisted passive and later active exercises may be started. These begin with pendulum exercises to start with, progressively increasing these by 20-30 degrees every week. Usually patients achieve the 90 degree restriction by fourth week. The patient is advised to repeat the exercises at home with a walking stick as active assisted exercises. Static Deltoid and static rotator cuff exercises are allowed only if these tissues are not part of the repair procedure.

These may be instituted from the first week itself. Therabands are not allowed till the protective phase is on for about six weeks.

Important Tips

- There cannot be standard recipe for all shoulder patients. Each patient is an individual and depending on their individual fitness, core stability and duration since affection they will each develop compensation manoeuvres which are different in each patient. These have to identified, diagnosed and treated accordingly. Design the programme around these deficits.

- On completion of phase I the patient is advised to proceed to a twice daily home programme for all the previous exercises for a period of one month when he/she is followed up.

- Perform Capsular stretches and Active assisted exercises with the patient lying down. This helps stabilise the scapula automatically, avoiding impingement,

- Scapular setting and proprioception restoration are best demonstrated practically during your actual programme to give you a palpatory feedback.

- It is important for patients to report to the physician of they have no improvement for a week or if they actually deteriorate.

- Most patients will achieve a full pain free function at the end of the four week home programme.

- It is advisable to do a UCLA score before phase I and at the end of phase II to establish objective criteria of improvement